

Transient global amnesia after ventricular fibrillation during acute myocardial infarction

Akut miyokard infarktüsü sırasında ventrikül fibrilasyonu sonrası gelişen geçici global amnezi

Murat Tulmaç¹, Vedat Şimşek¹, Ersel Dağ², Emine Tireli³, Özer Eser¹, Haksun Ebinç¹, Nesligül Yıldırım¹, Mehmet Tolga Doğru¹

¹Kırıkkale University, School of Medicine, Department of Cardiology, Kırıkkale

²Kırıkkale University, School of Medicine, Department of Neurology, Kırıkkale

³Kırıkkale High Specialization Hospital, Department of Neurology, Kırıkkale

Corresponding author: Murat TULMAÇ, Fabrikalar Mahallesi, Cemal Gürsel Caddesi, 35. Sokak No: 1 Ersoylar Apartmanı B Blok Daire 7, 71100, Kırıkkale, Tel: 0505 3197664, Faks: 0318 2124477, E-mail: mtulmac@yahoo.com

Geliş tarihi / Received: 26.04.2012

Kabul tarihi / Accepted: 30.04.2012

Abstract

Herein we report a 48 year old male patient who suffered from transient global amnesia after an immediately treated ventricular fibrillation during course of acute inferolateral myocardial infarction. Physicians should especially pay attention to detect transient global amnesia during management of patients with myocardial infarction complicated by ventricular fibrillation.

Key words: Transient global amnesia, myocardial infarction, ventricular fibrillation

Özet

Burada akut inferolateral miyokard infarktüsü seyrinde anında tedavi edilen ventrikül fibrilasyonu sonrası geçici global amnezi gelişen 48 yaşında bir erkek hastayı bildiriyoruz. Hekimler ventrikül fibrilasyonu ile komplike olan miyokard infarktüsü ile gelen hastalarda geçici global amnezi varlığını araştırmaya özellikle dikkat etmelidir.

Anahtar kelimeler: Geçici genel hafıza kaybı, miyokard infarktüsü, ventrikül fibrilasyonu

Introduction

Transient global amnesia (TGA) is characterized by anterograde memory disturbance of sudden onset with impairment of orientation in space and time, but undisturbed consciousness and identity, which usually resolves in hours with remaining persistent amnesia for the period of attack (1). In this report, we present a 48 year old male patient who suffered from transient global amnesia after an immediately treated ventricular fibrillation

during course of acute inferolateral myocardial infarction.

Case

A 48-year-old-man presented with acute inferolateral myocardial infarction (MI) was referred for primary percutaneous coronary intervention. In the emergency room of referring hospital he experienced ventricular fibrillation (VF) which was immediately treated by defibrillation. At admission to angiography laboratory he was mildly disoriented in

time and place without any accompanying focal neurological symptoms or signs, and diagnosed to have anterograde amnesia since the event. After computerized tomography scan of brain, by which hemorrhage was ruled out, totally occluded second obtuse margin branch of circumflex coronary artery was recanalized by percutaneous transluminal coronary angioplasty and stenting (Figure 1). Interestingly his left anterior descending coronary artery was anomalously originating from right coronary cusp with a transseptal course (Figure 2). He was then admitted to coronary care unit (CCU) under anticoagulant therapy. His blood glucose was normal (100mg/dl) and did not report any personal or family history of psychiatric disorder. Witnesses of VF did not report any head trauma. Any epileptiform activity was not observed on electroencephalography. During follow-up in CCU anterograde amnesia resolved in 10th hour of the event and cranial MR diffusion weighted imaging (DWI) did not reveal any pathology on 24th hour. Neurologic examinations before discharge and at 3 months later he was completely normal with the exception of amnesic gap.

Discussion

This is the first report of transient global amnesia after ventricular fibrillation, although immediately treated.

Predisposing factors associated with TGA include sudden immersion in cold or hot water, physical exertion, emotional or psychological stress, pain, medical procedures, sexual intercourse, and Valsalva-associated maneuvers (). Ischemia, migraine, epileptic seizure, venous congestion, and psychological disturbances are proposed

causes for this syndrome (). Recent evidence from MRI revealed involvement of hippocampal parenchyma in the pathophysiology of TGA(). Acute stress was shown to impair spatial memory retrieval by inducing hippocampal long-term depression (LTD) in rats(). It is recently reported that MRI signal changes in the course of a TGA are confined to the CA1 sector of the hippocampal cornu ammonis which are reversible and do not evolve into residual structural changes (). Selective vulnerability of the CA1 sector of hippocampal cornu ammonis to metabolic stress was suggested to play a pivotal part in the pathophysiological cascade leading to an impairment of hippocampal function during TGA().

Short term ischemia due to VF might have aggravated the effects of acute stress due to MI which impaired long-term potentiation and induced long-term depression of CA1 neurons. Physicians should especially pay attention to detect TGA during management of patients with MI complicated by VF.

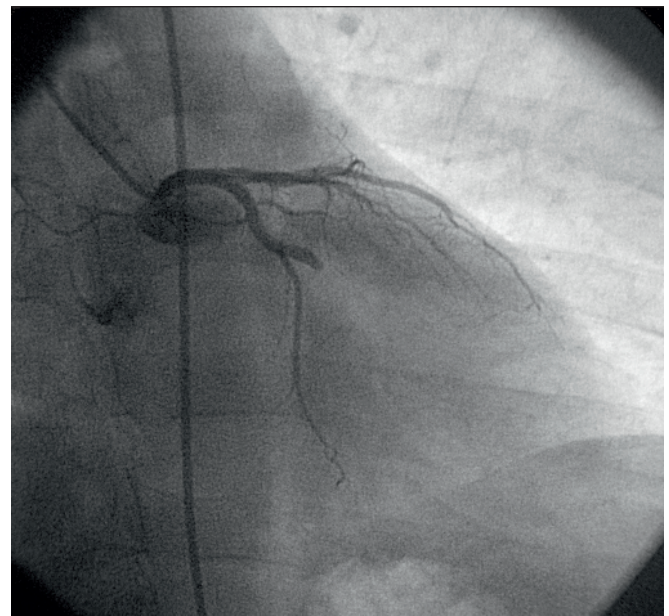


Figure 1: Occluded obtuse margin branch which caused acute inferolateral myocardial infarction

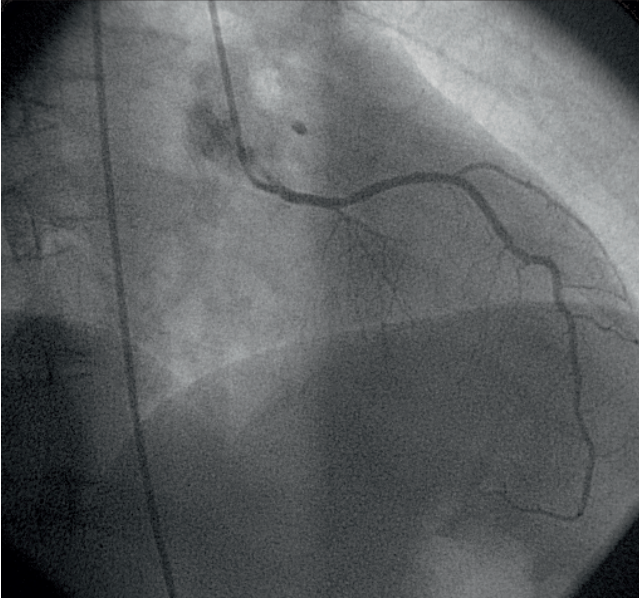


Figure 2: Left coronary artery originating from right coronary sinus

Yazarlarla ilgili bildirilmesi gereken konular (Conflict of interest statement) : Yok (None)

References

1)Bartsch T, Deuschl G. Transient global amnesia: functional anatomy and clinical implications. *Lancet Neurol* 2010;9(2):205-14.
2)Sander K, Sander D. New insights into transient global amnesia: recent imaging and clinical findings. *Lancet Neurol* 2005;4(7):437-44.

3)Sedlaczek O, Hirsch JG, Grips E, Peters CN, Gass A, Wohrle J, et al. Detection of delayed focal MR changes in the lateral hippocampus in transient global amnesia. *Neurology* 2004;62(12):2165-70.
4)Wong TP, Howland JG, Robillard JM, Ge Y, Yu W, Titterness AK, et al. Hippocampal long-term depression mediates acute stress-induced spatial

memory retrieval impairment. *Proc Natl Acad Sci U S A* 2007;104(27):11471-6.

5)Bartsch T, Alfke K, Stिंगele R, Rohr A, Freitag-Wolf S, Jansen O, et al. Selective affection of hippocampal CA-1 neurons in patients with transient global amnesia without long-term sequelae. *Brain* 2006;129(11):2874-84.